



Efficacy of wire-guided biopsy forceps for tissue sampling in endoscopic retrograde cholangiopancreatography: a preliminary experience

Manaswita Tappata¹, Nicholas M. McDonald², Mohamed Abdallah², Mohammad Bilal^{2,3}

¹Department of Internal Medicine, University of Minnesota Medical Center, Minneapolis, MN; ²Division of Gastroenterology and Hepatology, University of Minnesota Medical Center, Minneapolis, MN; ³Division of Gastroenterology and Hepatology, Minneapolis Veterans Affairs Health Care System, Minneapolis, MN, USA

Endoscopic retrograde cholangiopancreatography (ERCP) plays an important role in the diagnosis and management of biliary strictures and cholangiocarcinoma (CCA).¹ The diagnosis of CCA often requires a combination of bile duct biopsy, aspiration, and brushings. These techniques can be challenging because of the desmoplastic (fibrotic) characteristics of CCA, and the paucicellular nature of the tumor, leading to the presence of minimal malignant cholangiocytes.¹

Current techniques include brush cytology, bile duct biopsies via freehand cannulation of the bile duct using pediatric biopsy forceps, bile duct aspiration, and cholangioscopy-directed biopsies. Brush cytology has been the standard approach; however, it has low sensitivity, with studies reporting a detection rate ranging from 18% to 60%.² Cholangioscopy-directed biopsies are reported to have a sensitivity of 60% to 70%; however, they are limited by the endoscopists' expertise and availability and the cost of the procedure.^{3,4} Freehand biliary cannulation with tissue sampling using pediatric biopsy forceps is technically challenging, can be associated with adverse events such as

bleeding and perforation, and is limited by the small size of the sample that can be obtained.² The yield of pediatric forceps biopsy is moderate, with an overall sensitivity of 56%.² Bile duct aspiration has little additional advantage when compared to the other methods.⁵ When multiple methods are combined, such as with the combination of brush cytology and endoscopic biopsy, the cumulative yield improves to 70%.⁶

Recently, wire-guided (WG) biopsy forceps have been developed (Histoguide; Steris), which allow for the advancement of the standard-size biopsy forceps in the bile duct over a guide-wire. We present our experience with this new WG biopsy forceps in a series of patients undergoing ERCP for the evaluation of biliary strictures.

All consecutive patients who underwent ERCP with WG biopsy forceps for the evaluation of biliary stricture between October 2021 and November 2021 were included. The patient demographics and the clinical and procedural characteristics were also recorded. Endoscopic procedure reports were reviewed to determine the indications for the procedure, location of the stricture, interventions performed (bile duct biopsy, cholangioscopy-directed biopsies, brushings, aspiration), and location of the biopsy taken with the WG biopsy forceps. The clinical data collected included information on patient anatomy, final pathology results, and the 30-day adverse events. The primary outcomes of this study were the technical and clinical success rates. Technical success was defined as successful cannulation of the bile duct and tissue collection using the WG biopsy forceps. Clinical success was defined as an accurate his-

Received: May 20, 2022 Revised: July 1, 2022 Accepted: July 6, 2022

Correspondence: Mohammad Bilal

Division of Gastroenterology and Hepatology, Minneapolis Veterans Affairs Health Care System, 1 Veterans Drive, Minneapolis, MN 55417, USA

E-mail: billa17@hotmail.com

© This is an Open Access article distributed under the terms of the Creative Commons Attribution Non-Commercial License (<http://creativecommons.org/licenses/by-nc/4.0/>) which permits unrestricted non-commercial use, distribution, and reproduction in any medium, provided the original work is properly cited.

tological diagnosis of the biliary stricture. Secondary outcomes included sensitivity of the histological diagnosis obtained using the WG biopsy forceps compared to the conventional methods (bile duct brushings, aspiration) and procedure-related adverse events. Descriptive statistics were calculated for all the variables. This study was approved by the local institutional review board.

The novel WG biopsy forceps used in all patients is a WG forceps that measures 230 cm in length, has a channel diameter of 4.2 mm, and is compatible with a 0.035 inch guidewire. The catheter diameter is 2.1 mm, the jaw opening width is 8.0 mm, and the jaw diameter is 2.2 mm (Fig. 1). The forceps can pass over a guidewire and be used with a short-wire technique. The jaw of the biopsy forceps cannot be positioned over the guidewire, but the remainder of the catheter is placed over the guidewire.

All the procedures were performed by a single endoscopist. Biliary sphincterotomy was performed in all cases before using the WG biopsy forceps. The forceps were advanced into the bile duct over a 0.025 inch or a 0.035 inch guidewire (Fig. 1A, B), and all procedures were performed using the short-wire

technique. The WG forceps were then advanced to the level of the stricture under fluoroscopic guidance (Fig. 1C, D). The forceps was opened below the stricture, advanced towards the stricture, and closed while maintaining slight forward pressure on the forceps for tissue acquisition. Three to four samples were obtained per procedure.

Six consecutive patients underwent the ERCP procedure using the WG biopsy forceps to evaluate the biliary strictures. All patients were men with a median age of 73 years. The primary indication for the procedure was biliary stricture in all patients. The biliary strictures were located in the common bile duct ($n=4$) and hilum ($n=2$) (Table 1). All patients underwent tissue sampling using the WG forceps. Bile duct brushings for cytology were also performed in all patients. Single-operator cholangioscopy (SOC)-guided biopsies were performed in one patient concomitantly with the biopsy using the WG forceps, whereas one patient underwent SOC during a prior ERCP. The histopathologic findings were consistent with malignancy in five patients, while one patient had a benign stricture. The technical success rate of the WG forceps was 100%. The clinical

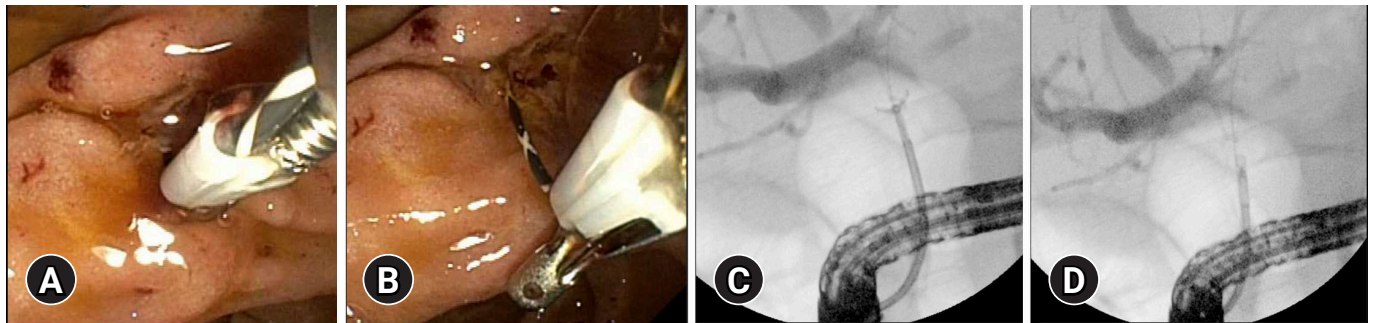


Fig. 1. (A) Endoscopic view showing wire-guided biopsy forceps being inserted into the papilla. (B) Side view of the forceps over a guidewire with the forceps open. (C) Fluoroscopic view of the open forceps in the hilum. (D) Fluoroscopic view of the closed forceps after tissue acquisition.

Table 1. Patient and procedural characteristics

Patient	Location of biliary stricture	Final pathology	Pathology of WG biopsy forceps	Pathology of SOC-directed biopsies	Pathology of bile duct aspiration	Pathology of brushings
1	Hilum	Malignant	Malignant	-	-	Malignant
2	Hilum	Malignant	Benign	Malignant	Benign	Benign
3	CBD	Malignant	Malignant	Indeterminate	Benign	Indeterminate
4	CBD	Malignant	Malignant	-	-	Malignant
5	CBD	Malignant	Malignant	-	-	Indeterminate
6	CBD	Benign	Benign	Benign	-	Benign
Diagnostic accuracy	-	-	0.83	0.66	0	0.5

WG, wire-guided; SOC, single-operator cholangioscopy; CBD, common bile duct; -, not applicable.

success rate was 83%. One patient with a hilar stricture required a repeat ERCP with SOC-directed biopsies to yield a diagnosis of malignancy. The accuracy for appropriate pathological diagnosis was 83% for WG biopsy forceps and 50% for biliary brushings. In one case, when the SOC-directed biopsies were indeterminate, a repeat ERCP using the WG biopsy forceps for tissue sampling yielded a diagnosis of malignancy. The clinical success rates of bile duct brushings and SOC-directed biopsy were 50% and 66%, respectively. There were no adverse events, need for admission, or mortality within 30 days of the procedure.

In this study, we report our preliminary experience with the use of WG biopsy forceps for the evaluation of biliary strictures during ERCP. Technical success was achieved in all patients, and the diagnostic accuracy (83%) of WG forceps was comparable to or higher than that of the other available modalities. In addition, the use of WG forceps was safe, with no reported adverse events.

Diagnostic strategies have also been evolving, including biomarkers, proteomic analysis by mass spectrometry, microRNA analysis, and fluorescence in situ hybridization in other biological specimens. Other reported techniques include the use of a longer cytology brush, which continues to have a low diagnostic yield of approximately 30%, or probe-based confocal laser endomicroscopy. Probe-based confocal laser endomicroscopy was evaluated in a multicenter study and showed increased diagnostic yield when combined with standard techniques; however, the technical complexity, resources needed for endoscopist training, and costs are barriers to its widespread use.⁷ One center developed a novel triple lumen catheter to allow the passage of larger biopsy forceps; however, its safety and efficacy have not yet been studied.⁸

SOC has been increasingly used because it provides direct visualization of strictures, allowing for targeted biopsies. The sensitivity described in prior studies is variable.⁹ A randomized controlled trial reported a sensitivity of 68% in detecting malignant strictures with SOC when compared with brushings.¹⁰ In a systematic review of ten studies, SOC biopsies had a sensitivity of 60.1% for detecting malignant strictures and a specificity of 97%.³ The lower sensitivity is attributed to the small size of the specimens that can be obtained. However, some of these data are from before the availability of the newer iteration of cholangioscopy-guided biopsy forceps (SpyBite Max; Boston Scientific). Overall, this method appears to be better than brush cytology, and its main limitations include the cost and the need for experienced endoscopists.

The ideal tissue sampling method is simple, safe, efficient, and inexpensive. The new WG biopsy forceps are a useful addition to the armamentarium of advanced endoscopists for tissue sampling during ERCP. These forceps are relatively easy to use and add little time to the procedure. In our preliminary analysis, WG forceps yielded a diagnosis in all cases, except for one case where there was the presence of hilar stricture. Although we had a technical success rate of 100%, one possible limitation of this tool is that the jaw part of the WG biopsy forceps is not positioned over the wire, and hence it can be challenging to advance it into the biliary tree in select cases, especially in those with an unstable duodenoscope position. Another possible limitation is that it might not be possible to achieve accurate tissue sampling for strictures in the hepatic hilum, intrahepatic ducts, or infiltrative strictures located mainly in the bile duct wall because the jaw portion of the device is not positioned over the guidewire and might not follow the guidewire once it enters the bile duct and intrahepatic ducts. However, all the cases included in this report were infiltrative strictures located mainly in the bile duct wall. Moreover, the biopsies are conducted under fluoroscopic guidance; therefore, endoscopic visualization was unavailable, as with cholangioscopy.

The limitations of this study include being a single-center study with small sample size, given the preliminary nature of the study. Hence the results likely do not represent a complete overview of the safety and efficacy of this method, and it would be beneficial to investigate this technique further in a larger number of patients at a variety of centers. Despite these limitations, our preliminary experience shows that WG biopsy forceps appear to be an effective, easy-to-use, and safe tool for tissue sampling in ERCP and are useful in evaluating biliary strictures during ERCP.

Conflicts of Interest

The authors have no potential conflicts of interest.

Funding

None.

Author Contributions

Conceptualization: MB; Data curation: MT, MB; Formal analysis: MT; Investigation: MB; Methodology: MB, NMM; Project administration: MT, NMM; Resources: MB; Software: MB; Writing—original draft: MT, NMM; Writing—review & editing: NMM, MA, MB.

ORCID

Manaswita Tappata <https://orcid.org/0000-0002-0249-2120>
Nicholas M. McDonald <https://orcid.org/0000-0003-3226-1718>
Mohamed Abdallah <https://orcid.org/0000-0002-1038-6512>
Mohammad Bilal <https://orcid.org/0000-0002-1784-212X>

REFERENCES

1. Lazaridis KN, Gores GJ. Cholangiocarcinoma. *Gastroenterology* 2005;128:1655–1667.
2. Korc P, Sherman S. ERCP tissue sampling. *Gastrointest Endosc* 2016;84:557–571.
3. Navaneethan U, Hasan MK, Lourdasamy V, et al. Single-operator cholangioscopy and targeted biopsies in the diagnosis of indeterminate biliary strictures: a systematic review. *Gastrointest Endosc* 2015;82:608–614.
4. Jang S, Stevens T, Kou L, et al. Efficacy of digital single-operator cholangioscopy and factors affecting its accuracy in the evaluation of indeterminate biliary stricture. *Gastrointest Endosc* 2020;91:385–393.
5. de Bellis M, Sherman S, Fogel EL, et al. Tissue sampling at ERCP in suspected malignant biliary strictures (Part 2). *Gastrointest Endosc* 2002;56:720–730.
6. Navaneethan U, Njei B, Lourdasamy V, et al. Comparative effectiveness of biliary brush cytology and intraductal biopsy for detection of malignant biliary strictures: a systematic review and meta-analysis. *Gastrointest Endosc* 2015;81:168–176.
7. Slivka A, Gan I, Jamidar P, et al. Validation of the diagnostic accuracy of probe-based confocal laser endomicroscopy for the characterization of indeterminate biliary strictures: results of a prospective multicenter international study. *Gastrointest Endosc* 2015;81:282–290.
8. Goetz M, Malek NP. Novel triple lumen catheter for ERCP tissue diagnosis. *Endosc Int Open* 2018;6:E984–E988.
9. Onoyama T, Hamamoto W, Sakamoto Y, et al. Peroral cholangioscopy-guided forceps biopsy versus fluoroscopy-guided forceps biopsy for extrahepatic biliary lesions. *JGH Open* 2020;4:1119–1127.
10. Gerges C, Beyna T, Tang RS, et al. Digital single-operator peroral cholangioscopy-guided biopsy sampling versus ERCP-guided brushing for indeterminate biliary strictures: a prospective, randomized, multicenter trial (with video). *Gastrointest Endosc* 2020;91:1105–1113.