

# Aortoduodenal fistula bleeding caused by an aortic stent graft

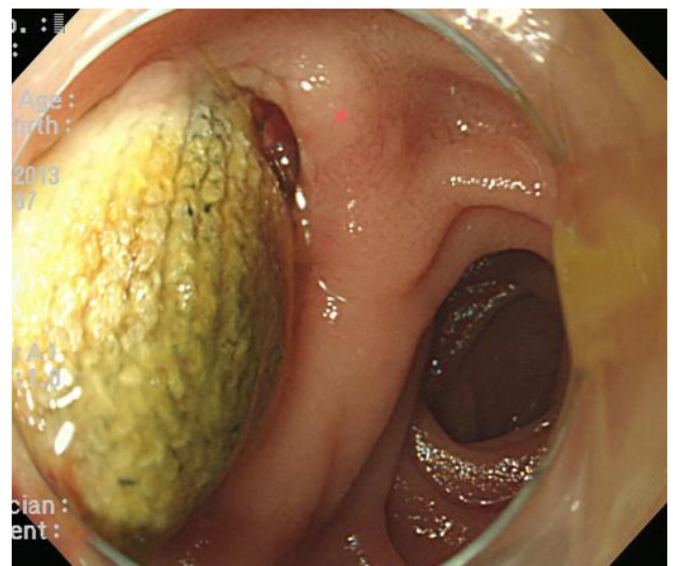Seunghyun Hong, Gwang Ha Kim

Department of Internal Medicine, Pusan National University School of Medicine and Biomedical Research Institute, Pusan National University Hospital, Busan, Korea

A 65-year-old female visited the emergency room due to sudden hematemesis and hematochezia. One year earlier, the patient underwent endovascular implantation of an aorto-bi-iliac bifurcation stent graft for a fusiform infrarenal aortic aneurysm that extended to the left common iliac artery. At the time of presentation, her blood pressure and heart rate were 70/40 mmHg and 105 beats/min, respectively. Laboratory findings showed a white blood cell count of 13,000/ $\mu$ L, hemoglobin level of 8.0 g/dL, and platelet count of 405,000/ $\mu$ L. Emergent endoscopy identified a foreign material (an aortic stent graft) with vascular pulsation in the third part of the duodenum (Fig. 1). Abdominal computed tomography revealed increased fat stranding around the aorta, which is indicative of inflammation, and a loss of the fat plane between the duodenum and aorta (Fig. 2). Therefore, the cause of bleeding was diagnosed as an aortoduodenal fistula caused by the previously placed aortic stent graft. The patient underwent primary closure of the duodenal perforation and omental wrapping and was discharged without any complications. However, the patient passed away 31 months later due to recurrence of the aortoduodenal fistula.

Aortoenteric fistula can occur secondary to aortic reconstruc-

tion procedures<sup>1</sup> and can develop anywhere in the gastrointestinal tract adjacent to the aorta; however, it is most frequently observed in the third part of the duodenum, which is anchored in the retroperitoneal space and positioned directly anterior to the aorta. The location of the duodenum in close proximity to the aorta makes it susceptible to fistula formation due to the constant transmission of pulsatile forces from the aorta.<sup>2</sup> Therefore, aortoduodenal fistula should be considered a potential cause of hematemesis or hematochezia in patients with a history of aortic stent graft.<sup>3</sup>

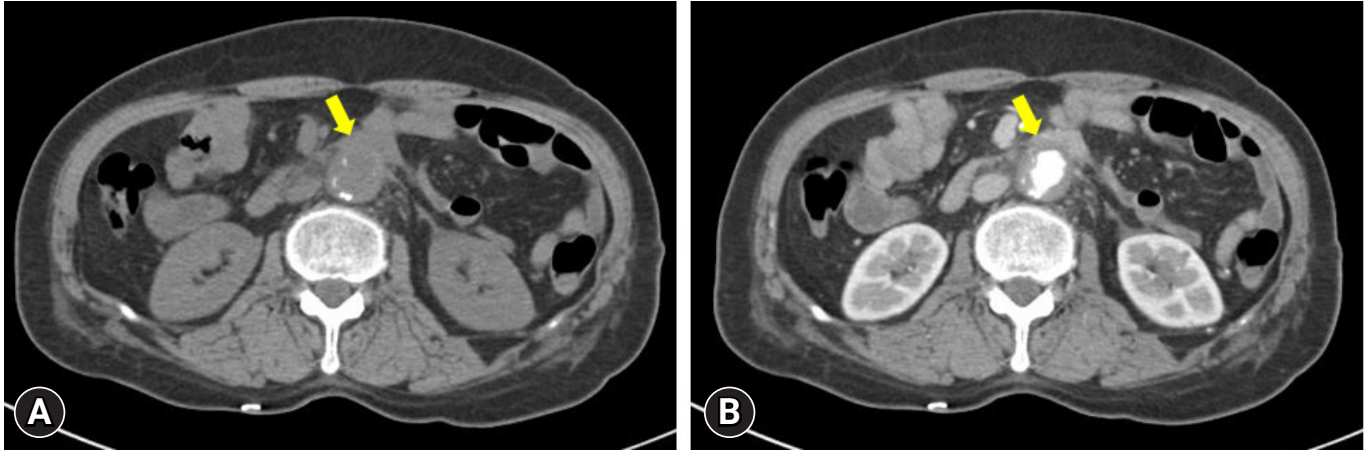


**Fig. 1.** Upper gastrointestinal endoscopy reveals a foreign material (an aortic stent graft) and blood clot with vascular pulsation (asterisk) in the third part of the duodenum.

Received: November 4, 2023 Revised: November 29, 2023  
 Accepted: November 30, 2023

**Correspondence:** Gwang Ha Kim  
 Department of Internal Medicine, Pusan National University School of Medicine and Biomedical Research Institute, Pusan National University Hospital, 179 Gudeok-ro, Seo-gu, Busan 49241, Korea  
 E-mail: doc0224@pusan.ac.kr

© This is an Open Access article distributed under the terms of the Creative Commons Attribution Non-Commercial License (<http://creativecommons.org/licenses/by-nc/4.0/>) which permits unrestricted non-commercial use, distribution, and reproduction in any medium, provided the original work is properly cited.



**Fig. 2.** Abdominal computed tomography reveals increased fat stranding around the aorta, which is indicative of inflammation, and a loss of the fat plane between the duodenum and aorta (arrows). (A) Pre-enhanced phase. (B) Arterial phase.

### Conflicts of Interest

Gwang Ha Kim is currently serving as a deputy editor for Clinical Endoscopy; however, he was not involved in the peer reviewer selection, evaluation, or decision process of this article. Seunghyun Hong has no potential conflicts of interest.

### Funding

None.

### Author Contributions

Conceptualization: GHK; Data curation: SH, GHK; Investigation: GHK; Methodology: SH; Writing–original draft: SH; Writing–review & editing: all authors.

### ORCID

Seunghyun Hong  
Gwang Ha Kim

<https://orcid.org/0009-0002-3982-8916>  
<https://orcid.org/0000-0001-9721-5734>

### REFERENCES

1. Kim BY, Kim KB. Primary aortoduodenal fistula causes massive melena: a case report. *Korean J Gastroenterol* 2021;77:132–135.
2. Janne d'Othée B, Soula P, Otal P, et al. Aortoduodenal fistula after endovascular stent-graft of an abdominal aortic aneurysm. *J Vasc Surg* 2000;31:190–195.
3. Kim SE, Kim HJ, Koh M, et al. A practical approach for small bowel bleeding. *Clin Endosc* 2023;56:283–289.